

Semi-Automated Three-Dimensional Condylar Reconstruction

Irene Méndez-Manjón, *MSC, PhD,*†*
 Haas J. Orion Luiz, *MSC, PhD,‡*
 Guijarro-Martínez Raquel, *MD, PhD,*†*
 Belle de Oliveira Rogério, *MSC, PhD,‡*
 Valls-Ontañón Adaia, *MD, PhD,*†*
 and Hernández-Alfaro Federico, *MD, PhD*†*

Abstract: The objective was to validate a semi-automated segmentation method for 3-dimensional (3D) reconstruction of the mandibular condyle from cone beam computed tomography (CBCT) data and illustrate its application in volumetric analysis of the condyle.

Ten CBCT datasets were used to validate the proposed semi-automatic method for 3D rendering of mandibular condyles. First, a standardized orientation protocol of the skull was applied. After defining the volume of interest, a grey-scale cut-off value was selected to allow an automatic reconstruction of the condyle's surface. Subsequently, condylar contour was optimized manually. The whole process was repeated twice by 2 independent investigators. Volumetric measurements of the condyle were used as a measure of conformity between both investigators. The reproducibility of condylar volume reconstruction was excellent for intra-examiner measurements (CV = 3.65%, intraclass correlation coefficient = 0.97) and good for inter-examiner measurements (CV = 7.15%, ICC = 0.89). The overall mean time required for the segmentation process was 6.31 + 2.78 minutes. The proposed protocol provides an accurate and reproducible tool for 3D reconstruction of the mandibular condyle using CBCT data. Its implementation will enable adequate follow-up of morphological changes in bone tissue with a Hounsfield unit-based imaging segmentation method.

Key Words: 3D imaging, condylar resorption, condyle, orthognathic surgery, 3-dimensional, TMJ

From the *Department of Oral and Maxillofacial Surgery, Universitat Internacional de Catalunya, Sant Cugat del Vallès; †Institute of Maxillofacial Surgery, Teknon Medical Center, Barcelona, Spain; and ‡Department of Oral and Maxillofacial Surgery, Pontifícia Universidade Católica do Rio Grande do Sul (PUCRS), Porto Alegre, Brazil.

Received April 29, 2019.

Accepted for publication May 18, 2019.

Address correspondence and reprint requests to Irene Méndez-Manjón, MSc, PhD, Institute of Maxillofacial Surgery, Teknon Medical Center, Vilana 12, D-185, 08022 Barcelona, Spain; E-mail: manjon.irene@uic.es

This study was approved by the Ethics Committees of Teknon Medical Centre and Universitat Internacional de Catalunya.

The authors report no conflicts of interest.

Supplemental digital contents are available for this article. Direct URL citations appear in the printed text and are provided in the HTML and PDF versions of this article on the journal's Web site (www.jcraniofacialsurgery.com).

Copyright © 2019 by Mutaz B. Habal, MD

ISSN: 1049-2275

DOI: 10.1097/SCS.00000000000005781

Positional and morphological changes of the mandibular condyles are frequently reported after orthognathic surgery procedures.^{1–7} At any rate, when positional changes do occur, their clinical significance is poorly understood. In this regard, several studies have demonstrated that the temporomandibular joints (TMJ) can adapt to small positional changes by undergoing physiological remodeling without secondary TMJ damage.^{1,8,9} However, other investigations have evidenced that positional changes of the condyle can promote postoperative occlusal instability and relapse,^{10,11} temporomandibular disorders (TMD),^{6,12} and progressive condylar resorption (PCR).^{13–18}

In particular, the commonly reported association between PCR and late postoperative relapse^{16,18–21} calls for the definition of an effective protocol to evaluate condylar morphology after orthognathic surgery.

Cone-beam computed tomography (CBCT) has become the imaging modality of choice for diagnosis and treatment planning in orthognathic surgery and orthodontics.^{22–24} It is an excellent low radiation dose alternative to conventional CT imaging,²⁵ with several other advantages. In particular, the possibility to build 3-dimensional (3D) virtual models with registration and to perform 3D superimposition has led to a definitive change in treatment planning and long-term evaluation in orthognathic surgery.²⁶ CBCT is also becoming the imaging modality of choice for the osseous components of the TMJ.²⁷ It has been shown that CBCT provides greater diagnostic accuracy than panoramic radiography and spiral tomography in the detection of condylar cortical erosion and osteophytes.^{28,29,30}

The prospect of using the same CBCT-based protocol to plan orthognathic surgery treatment and to study subsequent changes in condylar morphology over time would provide the invaluable advantage of reducing the number of imaging tests needed in each patient.

Despite the superior reliability of CBCT for the study of condylar morphology, some drawbacks persist. Segmentation and 3D rendering of the condyles are inherently difficult due to the low bone density of this region in comparison to the rest of the mandible and its close relation to the articular disc.³¹ In this context, several protocols have been proposed to establish a reproducible method for 3D rendering of the condylar surface.^{32–35} Nevertheless, most of these proposed protocols are based on manual outlining of the condylar contour in 2-dimensional (2D) cross-sections of the CBCT scan, a highly observer-dependent procedure. In fact, research has shown that the condyle and lingual aspect of the mandible are the most susceptible areas to observer experience.³¹ Moreover, this technique usually requires the use of additional software for data processing and is very time-consuming.

Recently, a semi-automated protocol for condyle rendering has been proposed to overcome the aforementioned limitations.³⁵ This protocol is based on 3D region-growing and local thresholding algorithms that require that the observer indicates a seed point every 5 slides. Thus, although both the process of manual outlining and processing time are substantially reduced, the observer's judgment still plays an important role.

The purpose of the present study is to validate a fast, semi-automated approach to 3D rendering of the condyles using 1 single software. This protocol is applicable to the analysis of condylar morphology changes over time as well as to orthognathic surgery planning.

METHODS

The Declaration of Helsinki guidelines were followed in all study phases. Approval from the Ethics Committee of the Universitat Internacional de Catalunya (Barcelona, Spain) and Teknon Medical Center (Barcelona, Spain) was obtained (reference number CIR-ECL-2012-03).

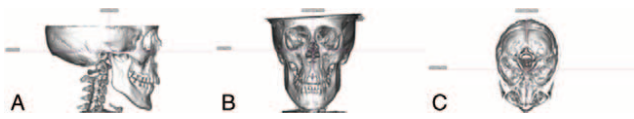


FIGURE 1. Head orientation. A. Frankfurt horizontal plane for pitch orientation. B. Roll axis was orientated by the frontozygomatic sutures bilaterally. C. Yaw orientation was defined by the crista galli and center of the magnum foramen.

The preoperative CBCT datasets of 10 adult Caucasian patients were randomly selected from the database of the Institute of Maxillofacial Surgery (Teknon Medical Center, Barcelona, Spain). Scans were obtained with an iCAT-Q Vision device, version 1.8.0.5 (Imaging Sciences International, Hatfield, Pennsylvania). The institution’s standard scanning conditions for orthognathic surgery patients were ensured: patient breathing quietly, sitting upright, with the clinical Frankfurt horizontal (FH) plane parallel to the floor, and the condyles in centric relation with the help of a wax wafer.³⁶ Preliminary data were saved in DICOM format. Image viewing and processing were carried out in a workstation (Intel Pentium 4 processor, 3.80 GHz, 120 GB hard drive, 2 GB RAM, operating system Microsoft Windows XP Professional SP5, minimum screen size 20 inches) running ICAT-Q Vision Imaging Sciences 1.8.0.5 and Dolphin Imaging 3D version 11.8 software (Dolphin Imaging & Management Solutions, Chatsworth, CA).

**Image Processing
Head Orientation**

In order to systematize the position of the 3D virtual model of each patient, a standardized orientation protocol was applied to the pitch, roll, and yaw axes.

The pitch axis was oriented taking the FH plane as a reference, defined bilaterally by the right and left 3D porion and right and left orbitale landmarks, as described by Cevidanes et al³⁷. The midsagittal plane (yaw) was defined by the crista galli and center of the magnum foramen. Finally, the roll axis was defined by the frontozygomatic sutures bilaterally (Fig. 1).

Semiautomatic Segmentation

Using the previously oriented 3D virtual models, 2 independent observers segmented a total of 20 condyles in Dolphin Imaging 3D version 11.8 software. Observer 1 (OLH) had no experience with segmentation of condyles based on CBCT data, while observer 2 (IMM) had extensive experience on manual outlining-based segmentation of condyles. The overall segmentation process was repeated twice by each, with a 4-week interval between sessions.

Step 1: Determination of the Volume of Interest

In order to isolate the region of the mandibular condyle, the C-point was identified as the most caudal point of the sigmoid notch bilaterally, as described by Xi et al.³⁴

A built-in software tool (head plane parallel to the FP that passes through the C-point) was used to isolate the volume of interest.

Step 2: Semiautomatic Segmentation

A grey-scale cut-off value was selected to allow an automatic reconstruction of the condyle. The software assigns a Hounsfield value for that gray scale (80-11717 HU) so that scale was set in the software in order to standardize 3D rendering of the condyles for volumetric evaluation (Fig. 2). This tool creates a color map based on the available range of the software, which allows the operator to distinguish the boundaries of the surface outline of the condyle. The observer reduced the window until no green color could be observed

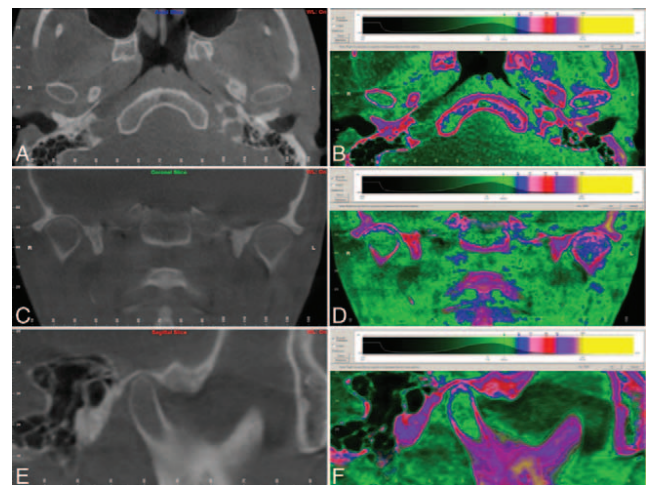


FIGURE 2. Case 2, CBCT. A. Axial view of condyles. B. Axial view of condyles with Hounsfield scale. C. Coronal view of condyles. D. Coronal view of condyles with Hounsfield scale. E. Sagittal view of condyles. F. Sagittal view of condyles with Hounsfield scale. CBCT, cone beam computed tomography.

(in other words, until all the area corresponded to >80 HU). Finally, the reconstruction was edited using the “sculpting” tool to eliminate any data outside the area of interest (Fig. 3). Subsequently, the volume of the resulting reconstruction and the mean HU were obtained. After applying the HU range to segment the condyle, the total volume of the skull was also obtained to test the method.

Statistical Analysis

Condylar volumes and mean HU for each segmented condyle were calculated within the 2 groups (Investigator 1. and Investigator 2). Statistical analysis was carried out in IBM SPSS Statistics for Windows (IBM Corp; Armonk, NY). The level of significance was set at 5% ($\alpha = 0.05$).

For a paired-samples *t* test, considering a medium effect size (0.5) for detection, the achieved power was 0.56 for a confidence level of 95%. The intraclass correlation coefficient (ICC) was calculated using the volumetric measurements as a measure of conformity between both observers. An ICC <0.51 was considered

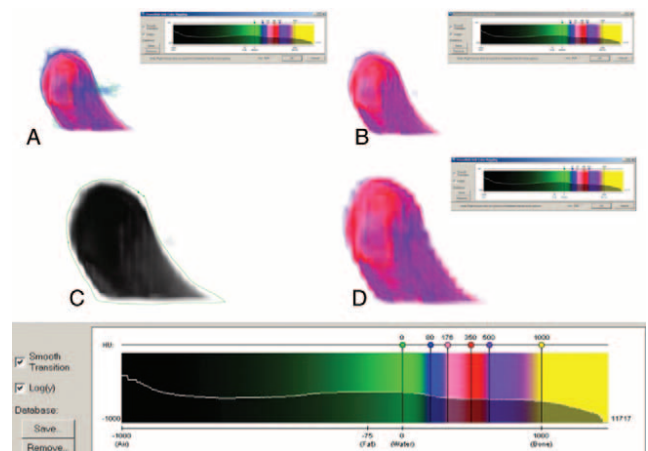


FIGURE 3. Semi-automated protocol for condyle segmentation and specific Hounsfield unit scale. A. Condyle without automated segmentation by Hounsfield units. B. Condyle with automated segmentation by Hounsfield units. C. Manual segmentation of the condyle for refinement. D. Segmented condyle with confirmation of Hounsfield units.

as poor, 0.51 to 0.70 as moderate, 0.71 to 0.90 as good and >0.90 as excellent.

RESULTS

The study group consisted of 10 patients (5 males and 5 females). A total of 20 condyles were segmented in each group. Variances and ICCs of volumetric measurement error were calculated. The mean duration of the segmentation process for observer 1 was 6.78 ± 3.42 minutes at T1 and 6.29 ± 2.69 minutes at T2. The mean time for the observer 2 was 6.29 ± 2.69 minutes at T1 and 5.88 ± 2.33 minutes at T2.

The mean overall condylar volume was found to be 1481.95 mm^3 by observer 1 and 1889.38 mm^3 by observer 2. The mean overall HU level of the condyle was 341.79 for observer 1 and 329.88 for observer 2.

Reproducibility of condylar volume measurements was excellent for intra-examiner parameters ($CV = 3.65\%$, $ICC = 0.97$) and good for inter-examiner parameters ($CV = 7.15\%$, $ICC = 0.89$). Reproducibility of the mean HU was excellent for both intra-examiner ($CV = 2.54\%$, $ICC = 0.99$) and inter-examiner parameters ($CV = 4.98\%$; $ICC = 0.96$) (Supplemental Digital Content 1, Table S1, <http://links.lww.com/SCS/A780>).

The CV and ICC were 0 and 1 respectively for the cranial volume in the intra-observer measurements.

Dahlberg's error (D) and CV were recalculated for low-density (<320 HU) and high-density (>320 HU) condyles. Working with low-density condyles did not seem to increase the error between examiners with this segmentation method (Supplemental Digital Content 1, Table S2, <http://links.lww.com/SCS/A780>).

A direct, moderate magnitude relationship between cranial density and condylar density was observed ($r = 0.552$, $P = 0.098$).

DISCUSSION

CBCT has proven its reliability in the assessment of condylar lesions, with greater reliability and accuracy than panoramic radiography and multislice CT.^{27–30} Three-dimensional models from CBCT data provide additional diagnostic information on morphology and exact location of the bony lesion in the condyle.

In this context, several authors have described its application in the study of an extensive variety of TMDs, such as osteoarthritis,^{32,33} trauma,²⁷ erosions,²⁹ osteophytes,²⁸ and developmental abnormalities.^{27,38} In the field of orthognathic surgery, superimposition of 3D reconstructions from CBCT data allows not only the evaluation of changes in condylar morphology^{39,40} and volume but also of potential positional changes of the condyle during the postoperative period.^{4,41,9,42} This eliminates the need to perform linear measurements in 2D slices from CT scans, which have the inherent drawback of landmark identification in a non-fixed structure such as the condyle.

This 3D analysis of the condylar morphology and surface offers the clinician the possibility of detecting early signs of progressive condylar resorption and anticipating the possible consequences of late relapse. In this sense, Xi et al¹⁸ showed that, in 3D analyses, patients with a reduction of condylar volume greater than 17% developed significant relapse in the horizontal and vertical direction. Although these data are based on a small sample, they pave the way for a new line of research that would allow establishment of thresholds to distinguish condylar remodeling from condylar resorption during postoperative follow-up.

The preoperative analysis of condylar morphology through 3D reconstructions also gives clinicians the opportunity to identify possible risk factors or developmental deformities, such as condylar hyperplasia, at the start of treatment.³⁸ Some conditions, such as small preoperative condylar volume,¹⁸ osteoarthritis, and posterior

inclination of the condylar neck, have been associated with a higher risk of PCR.²¹ Moreover, it has been shown that patients with a class II skeletal structure have a significantly smaller preoperative condylar volume than class I and class III patients.⁴³ Given current knowledge of these prognostic factors, long-term morphological changes should be included in the usual assessment protocol.

Considering that several studies have reported condylar remodeling and resorption after orthognathic surgery,^{15,21,44,45} the establishment of a rapid, user-friendly protocol for the evaluation of condylar morphology is crucial.

Different segmentation protocols have been proposed to obtain adequate 3D reconstructions of the condylar surface.^{32–35} However, some of the proposed methods are based on manual outlining of the condylar contour in 2D cross-sections, which is highly observer-dependent and time-consuming.^{33,46} In fact, the condyle has been referred to as one of the more difficult areas to segment, due to its low density in comparison to the rest of the mandible and the difficulty of isolating it from the articular disc.³¹

These early methods, besides the aforementioned drawbacks, required the use of several software products, which further hinders or even prevents the generalized use by all clinicians without the help of a specialized technician. In the present validation study, results obtained by an experienced observer in manual outlining segmentation were compared to those of an inexperienced observer. Good inter-examiner reproducibility was observed ($CV = 7.15\%$, $ICC = 0.89$), illustrating the fact that this method can be applied easily by clinicians without the need for a specialized technician.

As mentioned, the significantly lower bone density of the condyle in comparison to the rest of the mandible is one of the main reasons for the difficulty of its segmentation.³¹ In this sense, Schlueter et al⁴⁷ performed a validation study with 50 dry human condyles to determine the ideal window for 3D reconstruction of the condyle by CBCT. They found that morphological evaluation of the condyle using CBCT-based 3D reconstructions was most accurate when performed at density levels below those recommended for osseous examination. Based on these findings, we set our HU range in the software below osseous levels. Later, the refinement process was performed, obtaining an excellent intra-examiner ($CV = 3.65\%$, $ICC = 0.97$) and good inter-examiner ($CV = 7.15\%$, $ICC = 0.89$) reproducibility for condylar volume examination.

Additionally, we observed that, by applying this HU-based segmentation method, the higher susceptibility to segmentation error due to low condylar density could be eliminated. When analyzing the error between examiners for low- and high-density condyles, there was no greater tendency to error when working with low-density bone.

Based on the discussed limitations and the importance of establishing a user-friendly, rapid method accessible to all clinicians involved in condylar morphology analysis, some researchers have made important efforts towards developing efficient techniques. The protocol proposed by Xi et al,³⁵ based on 3D region-growing and local thresholding algorithms, reduced time and operator dependence significantly, thereby increasing the method's efficiency. However, their method implies the selection of 1 seed point every 5 slides, such that the observer's judgment still plays a fundamental role. Our proposed protocol gives clinicians the opportunity to monitor condylar morphology of orthognathic surgical patients over time in the same software environment used for planning. This makes the suggested method more convenient and effective for the clinician, reducing costs, time, and obviating the need for a dedicated technician.

As noted, excellent intra-examiner and good inter-examiner reproducibility were obtained for condylar volume measurements with an average image processing time of less than 6 minutes—less

than half the time required by the fastest segmentation protocol published to date.³⁵

In our study, the total volume of the skull after applying the HU range for the condyle was used to test the method. The CV and ICC were 0 and 1 respectively for cranial volume in intra-observer measurements. This means that the error in condylar segmentation occurs during the manual refinement process, not at the time of applying the HU range selected in the software. These results corroborate the fact that the greater the observer-dependence of the process, the greater error accumulation can be expected. Therefore, methods that reduce or eliminate the number of manual interactions^{34,35} seem not only to shorten processing time but also to increase the reliability of the method.

In conclusion, the proposed protocol showed excellent intra-observer and good inter-observer reproducibility for 3D assessment of condylar volume. The marked reduction of processing time achieved and the use of 1 single software to plan and monitor cases over time make the method highly efficient.

REFERENCES

- Kim Y-I, Cho B-H, Jung Y-H, et al. Cone-beam computerized tomography evaluation of condylar changes and stability following two-jaw surgery: Le Fort I osteotomy and mandibular setback surgery with rigid fixation. *Oral Surg Oral Med Oral Pathol Oral Radiol Endod* 2011;111:681
- Chen S, Lei J, Wang X, et al. Short- and long-term changes of condylar position after bilateral sagittal split ramus osteotomy for mandibular advancement in combination with Le Fort I osteotomy evaluated by cone-beam computed tomography. *J Oral Maxillofac Surg* 2013;71:1956
- Harris MD, Sickels JE Van, et al. Factors influencing condylar position after the bilateral sagittal split osteotomy fixed with bicortical screws. *J Oral Maxillofac Surg* 1999;57:650
- Méndez-Manjón I, Guijarro-Martínez R, Valls-Ontañón A, et al. Early changes in condylar position after mandibular advancement: a three-dimensional analysis. *Int J Oral Maxillofac Surg* 2016;45:787–792
- Bailey L, Tany J, Cevidanes LHS, et al. Stability and predictability of orthognathic surgery. *Am J Orthod Dentofac Orthop* 2004;126:273–277
- Saka B, Petsch I, Hingst V, et al. The influence of pre- and intraoperative positioning of the condyle in the centre of the articular fossa on the position of the disc in orthognathic surgery. A magnetic resonance study. *Br J Oral Maxillofac Surg* 2004;42:120–126
- An S-B, Park S-B, Kim Y-I, et al. Effect of post-orthognathic surgery condylar axis changes on condylar morphology as determined by 3-dimensional surface reconstruction. *Angle Orthod* 2014;84:316–321
- Cevidanes LHS, Bailey LJ, Tucker SF, et al. Three-dimensional cone-beam computed tomography for assessment of mandibular changes after orthognathic surgery. *Am J Orthod Dentofac Orthop* 2007;131:44
- Kim Y-I, Jung Y-H, Cho B-H, et al. The assessment of the short- and long-term changes in the condylar position following sagittal split ramus osteotomy (SSRO) with rigid fixation. *J Oral Rehabil* 2010;37:262–270
- Gerressen M, Stockbrink G, Smeets R, et al. Skeletal stability following bilateral sagittal split osteotomy (BSSO) with and without condylar positioning device. *J Oral Maxillofac Surg* 2007;65:1297–1302
- Ueki K, Marukawa K, Shimada M, et al. Condylar and disc positions after sagittal split ramus osteotomy with and without Le Fort I osteotomy. *Oral Surg Oral Med Oral Pathol Oral Radiol Endod* 2007;103:342–348
- Frey DR, Hatch JP, Sickels JE, et al. Effects of surgical mandibular advancement and rotation on signs and symptoms of temporomandibular disorder: a 2-year follow-up study. *Am J Orthod Dentofac Orthop* 2008;133:490.e1
- Arnett GW, Milam SB, Gottesman L. Progressive mandibular retrusion-idiopathic condylar resorption. Part I. *Am J Orthod Dentofac Orthop* 1996;110:8–15
- Arnett GW, Milam SB, Gottesman L. Progressive mandibular retrusion-idiopathic condylar resorption. Part II. *Am J Orthod Dentofac Orthop* 1996;110:8–15
- Cutbirth M, Sickels JE Van, Thrash WJ. Condylar resorption after bicortical screw fixation of mandibular advancement. *J Oral Maxillofac Surg* 1998;56:178–182
- Hoppenreijts TJ, Stoelinga PJ, Grace KL, et al. Long-term evaluation of patients with progressive condylar resorption following orthognathic surgery. *Int J Oral Maxillofac Surg* 1999;28:411–418
- Yamada K, Hanada K, Hayashi T, et al. Condylar bony change, disk displacement, and signs and symptoms of TMJ disorders in orthognathic surgery patients. *Oral Surg Oral Med Oral Pathol Oral Radiol Endod* 2001;91:603
- Xi T, Schreurs R, Loon B Van, et al. 3D analysis of condylar remodelling and skeletal relapse following bilateral sagittal split advancement osteotomies. *J Cranio-Maxillofacial Surg* 2015;43:462–468
- Kobayashi T, Izumi N, Kojima T, et al. Progressive condylar resorption after mandibular advancement. *Br J Oral Maxillofac Surg* 2012;50:176–180
- Park S-BB, Yang Y-MM, Kim Y-I II et al. Effect of bimaxillary surgery on adaptive condylar head remodeling: metric analysis and image interpretation using cone-beam computed tomography volume superimposition. *J Oral Maxillofac Surg* 2012;70:1951
- Hoppenreijts TJ, Freihofer HP, Stoelinga PJ, et al. Condylar remodelling and resorption after Le Fort I and bimaxillary osteotomies in patients with anterior open bite. A clinical and radiological study. *Int J Oral Maxillofac Surg* 1998;27:81–91
- Hernández-Alfaro F, Guijarro-Martínez R. New protocol for three-dimensional surgical planning and CAD/CAM splint generation in orthognathic surgery: an in vitro and in vivo study. *Int J Oral Maxillofac Surg* 2013;42:1547–1556
- Swennen GRJ, Mollemans W, Schutyser F. Three-dimensional treatment planning of orthognathic surgery in the era of virtual imaging. *J Oral Maxillofac Surg* 2009;67:2080–2092
- Gateno J, Xia J, Teichgraber JF, et al. A new technique for the creation of a computerized composite skull model. *J Oral Maxillofac Surg* 2003;61:222–227
- Mah J, Hatcher D. Three-dimensional craniofacial imaging. *Am J Orthod Dentofac Orthop* 2004;126:308
- Grauer D, Cevidanes LSH. NIH Public Access. *Am J Orthod Dentofac Orthop* 2010;126:460–470
- Barghan S, Tetradis S, Mallya S. Application of cone beam computed tomography for assessment of the temporomandibular joints. *Aust Dent J* 2012;57:109–118
- Salemi F, Shokri A, Mortazavi H, et al. Diagnosis of simulated condylar bone defects using panoramic radiography, spiral tomography and cone-beam computed tomography: a comparison study. *J Clin Exp Dent* 2015;7:e34
- Honey OB, Scarfe WC, Hilgers MJ, et al. Accuracy of cone-beam computed tomography imaging of the temporomandibular joint: comparisons with panoramic radiology and linear tomography. *Am J Orthod Dentofac Orthop* 2007;132:429–438
- Marques AP, Perrella A, Arita ES, et al. Assessment of simulated mandibular condyle bone lesions by cone beam computed tomography. *Braz Oral Res* 2010;24:467–474
- Engelbrecht WP, Fourie Z, Damstra J, et al. The influence of the segmentation process on 3D measurements from cone beam computed tomography-derived surface models. *Clin Oral Investig* 2013;17:1919–1927
- Cevidanes LHS, Hajati AK, Paniagua B, et al. Quantification of condylar resorption in temporomandibular joint osteoarthritis. *Oral Surgery, Oral Med Oral Pathol Oral Radiol Endodontol* 2010;110:110–117
- Paniagua B, Cevidanes L, Walker D, et al. Clinical application of SPHARM-PDM to quantify temporomandibular joint osteoarthritis. *Comput Med Imaging Graph* 2011;35:345–352
- Xi T, Loon B Van, Fudalej P, et al. Validation of a novel semi-automated method for three-dimensional surface rendering of condyles using cone beam computed tomography data. *Int J Oral Maxillofac Surg* 2013;42:1023–1029
- Xi T, Schreurs R, Heerink WJ, et al. A novel region-growing based semi-automatic segmentation protocol for three-dimensional condylar reconstruction using cone beam computed tomography (CBCT). *PLoS One* 2014;9:e111126

36. Hernández-Alfaro F, Guijarro-Martínez R, Mareque-Bueno J. Effect of mono- and bimaxillary advancement on pharyngeal airway volume: cone-beam computed tomography evaluation. *J Oral Maxillofac Surg* 2011;69:e395–400
37. Cevidanes L, Oliveira AEF, Motta A, et al. Head orientation in CBCT-generated cephalograms. *Angle Orthod* 2009;79:971–977
38. Hernández-Alfaro F, Méndez-Manjón I, Valls-Ontañón A, et al. Minimally invasive intraoral condylectomy: proof of concept report. *Int J Oral Maxillofac Surg* 2016;45:1108–1114
39. Ha M-H, Kim Y-I, Park S-B, et al. Cone-beam computed tomographic evaluation of the condylar remodeling occurring after mandibular setback by bilateral sagittal split ramus osteotomy and rigid fixation. *Korean J Orthod* 2013;43:263–270
40. Assis Ribeiro Carvalho F de, Cevidanes LHS, Motta ATS da, et al. Three-dimensional assessment of mandibular advancement 1 year after surgery. *Am J Orthod Dentofac Orthop* 2010;137:1
41. Kim H-M, Baek S-H, Kim T-Y, et al. Evaluation of three-dimensional position change of the condylar head after orthognathic surgery using computer-aided design/computer-aided manufacturing-made condyle positioning jig. *J Craniofac Surg* 2014;00:1
42. Draenert FG, Erbe C, Zenglein V, et al. 3D analysis of condylar position after sagittal split osteotomy of the mandible in mono- and bimaxillary orthognathic surgery - a methodology study in 18 patients. *J Orofac Orthop* 2010;71:421–429
43. Saccucci M, D’Attilio M, Rodolfo D, et al. Condylar volume and condylar area in class I, class II and class III young adult subjects. *Head Face Med* 2012;8:1
44. Peterson LJ, Hwang S-JMD, Haers PEMD, et al. Surgical risk factors for condylar resorption after orthognathic surgery. *Oral Surgery, Oral Med Oral Pathol Oral Radiol Endod* 2000;89:542
45. Wohlwender I, Daake G, Weingart D, et al. Condylar resorption and functional outcome after unilateral sagittal split osteotomy. *Oral Surg Oral Med Oral Pathol Oral Radiol Endod* 2011;112:315–321
46. Schilling J, Gomes LCR, Benavides E, et al. Regional 3D superimposition to assess temporomandibular joint condylar morphology. *Dentomaxillofac Radiol* 2014;43:20130273
47. Schlueter B, Kim KB, Oliver D, et al. Cone beam computed tomography 3D reconstruction of the mandibular condyle. *Angle Orthod* 2008;78:880–888